

## Thoracic cord compression by solitary osteochondroma

Verajit Chotmongkol, M.D.\*,  
Banchong Mahaisavariya, M.D.\*\*,  
Benjaporn Nitinavakarn, M.D.\*\*\*,  
Anucha Puapairoj, M.D.\*\*\*\*

\*Department of Medicine  
\*\*Department of Orthopaedics  
\*\*\*Department of Radiology  
\*\*\*\*Department of Pathology  
Faculty of Medicine, Khon Kaen University,  
Khon Kaen 40002, Thailand.

### ภาวะไขสันหลังถูกกดทับจากเนื้องอก osteochondroma

วีรจิตต์ โชติมงคล, พ.บ.\*, บรรจง มไหสวริยะ, พ.บ.\*\*

เบญจพร นิตินาวการ, พ.บ.\*\*\*, อนุชา พัวไพโรจน์, พ.บ.\*\*\*\*

\*ภาควิชาอายุรศาสตร์ \*\*ภาควิชาออร์โธปิดิกส์

\*\*\*ภาควิชารังสีวิทยา \*\*\*\*ภาควิชาพยาธิวิทยา คณะแพทยศาสตร์ มหาวิทยาลัยขอนแก่น

เนื้องอก osteochondroma ของกระดูกสันหลังเป็นภาวะที่พบน้อยมาก ผู้เขียนได้รายงานผู้ป่วยหญิงอายุ 72 ปี มีอาการอ่อนแรงและชาของขาทั้งสองข้างทันทีทันใด. การตรวจ myelography พบไขสันหลังถูกกดจากด้านนอกบริเวณ T<sub>10-11</sub> ผลการผ่าตัดพบเนื้องอกของกระดูก T<sub>11</sub> การตรวจทางพยาธิของเนื้องอกเข้าได้กับ osteochondroma. ดังนั้นเนื้องอกนี้จึงควรนึกถึงและสืบค้นหา ในผู้ป่วยที่มีอาการผิดปกติทางไขสันหลังที่เกิดขึ้นอย่างรวดเร็ว

The most common form of primary extradural spinal cord tumor in adults are chordomas and sarcomas<sup>(1)</sup>. Involvement of the spinal cord from vertebral osteochondroma is indeed rare<sup>(2,4)</sup>. Ladpli reported 90 cases of spinal cord tumors and osteochondroma was not found<sup>(5)</sup>. The serious neurological manifestation

of vertebral osteochondroma is spinal cord compression and usually presents with slow progression of motor and/or sensory deficits<sup>(3,4,6,7)</sup> (Table 1). We report a patient with thoracic osteochondroma who presented with sudden onset of paraplegia.

## CASE REPORT

A 72-year-old woman was admitted to the Srinagarind Hospital because of weakness and numbness of both legs. She had been in good health before this illness. About three weeks before admission, she developed sudden onset of weakness of both legs which flopped her to the floor while she was walking. There were no back pain and disturbance of sphincter function. These symptoms were stable until admission. No significant familial histories were noted.

On physical examination, she was alert. Her temperature was 36.7°C, blood pressure was 100/60 mmHg, respiration rate was 18/min and pulse rate was 80/min. Examination of vertebral column was unremarkable and no back tenderness. Neurological examination revealed hyperreflexic spastic paraplegia, predominate on the left, with bilateral Babinski's response. Loss of pin prick sensation below the level of T<sub>12</sub> and joint position sensation of both feet were noted. The anal sphincter tone was normal. The other findings were unremarkable.

Laboratory tests including complete blood count, blood chemistry, urine analysis, VDRL and cerebrospinal fluid analysis were normal. Chest X-ray was normal and thoraco-lumbar spine showed evidence of lumbar spondylosis. Myelography was performed through the L<sub>3</sub> puncture and showed evidence of extradural defect upon left side of T<sub>10-11</sub> with nearly complete obstruction. Extrinsic spinal cord compression at T<sub>10-11</sub> was diagnosed and operation was then performed.

Operative finding revealed that the spinal cord was compressed by bone mass, size 1 cm. in diameter, which extended from the left pedicle of T<sub>11</sub>. Total laminectomies of T<sub>10,11</sub> was performed and bone tumor was removed.

Microscopic examination of bone tumor was compatible with osteochondroma (Fig. 1). The post operative course was uncomplicated. Her muscle power was slightly improved.

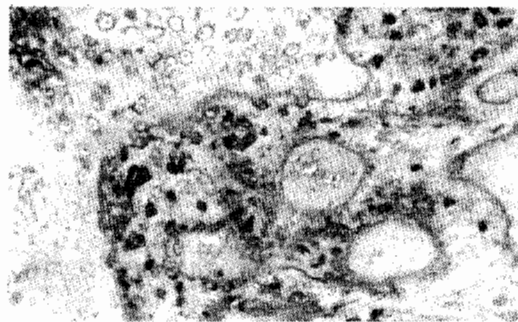


Figure 1. Section revealed that the tumor composed of trabeculae of mature bone (left) and an outer of cartilage (right). (H & E  $\times$  400)

## DISCUSSION.

Osteochondroma is the most common form of the benign bone tumors<sup>(8,9)</sup>. It can be classified into two groups: solitary and multiple osteochondroma<sup>(9)</sup>. The latter has numerous osteochondromas affecting many bones and is a much smaller group of patients, about 10% of cases<sup>(8,10)</sup>. Also, multiple osteochondromas usually have a strong familial tendency (Hereditary multiple exostosis) which transmitted by a single autosomal dominate gene and the incidence of development of secondary chondrosarcoma is higher, probably more than 10 percent<sup>(8)</sup>.

Osteochondromas can be found in all age groups and sexes, predominate in males. Approximately 40-60 percent of cases were less than twenty years of age at the time of excision of their tumors<sup>(8,10)</sup>.

Osteochondromas may occur on any bone that develops by enchondral ossifica-

tion. They usually occur in the metaphyseal region of the long bone of the limbs but rarely occur at the spine<sup>(8-10)</sup>. Dahlin reviewed 516 solitary lesions of this tumor and found only 17 cases (3.2%) at the spine<sup>(8)</sup>. Sampatanulul reported 78 cases of osteochondromas and was not found this tumor at the spine<sup>(10)</sup>.

The patients' symptoms are related to the size and location of the tumor. The complaint of a hard swelling, usually of long duration, is the most common. Spinal cord compression is rarely occurred.

Spinal osteochondroma can be found in all parts of the spine and the serious complication is spinal cord compression. Both motor and sensory defects are usually presented on initial examination and show more slowly progression. The optimal treatment is laminectomy and excision of the tumor which gives a good recovery of neurological deficits<sup>(3,4,6,7)</sup>

Our patient demonstrated four unusual presentations of solitary osteochondroma. First, she was an old female. Second, she had a solitary osteochondroma of T<sub>11</sub>. Third, she was developed spinal cord compression from this tumor. Lastly, her symptoms presented with sudden onset of neurological deficits which its pathophysiology may be from vasculopathy, secondary from pressure effect of tumor compression. Then osteochondroma should be aware in the case of sudden onset of spinal cord compression.

## SUMMARY

A 72-year-old woman with sudden onset of weakness and numbness of lower extremities was reported. Myelography demonstrated extradural compression of T<sub>10-11</sub>. Operative finding revealed spinal cord compression by bone tumor which extended from the pedicle of T<sub>11</sub>. Microscopic examination of tumor was compatible with osteochondroma. This rare tumor should be considered in the patient with sudden onset of spinal cord compression.

## REFERENCES

1. Pattern J. Neurological Differential Diagnosis. New York : Harold Starke Limited, 1978.
2. Adams RD, Victor M. Principles of Neurology. New York : Mc Graw-Hill Book Company, 1985.
3. Julien J, Riemens V, Vital C et al. Cervical cord compression by solitary osteochondroma of the atlas. *J Neurol Neurosurg Psychiatr* 1978; 41:479-81.
4. Loftus CM, Rozario RA, Prager R, et al. Solitary osteochondroma of T<sub>4</sub> with thoracic cord compression. *Surg Neurol* 1980; 13:355-7.
5. Ladpli S. Spinal Cord Tumors-A Clinical Analysis of 90 Cases. *Siriraj Hosp Gaz* 1986; 38:281-90.
6. Madigan R, Worrall T, McClain EJ. Cervical cord compression in Hereditary Multiple Exostosis. *J Bone Joint Surg [Am]* 1974;56:401-4.
7. Burr T, Morch MM. Hereditary multiple exostoses with spinal cord compression. *J Neurol Neurosurg Psychiatr* 1983; 46:96-8.
8. Dahlin DC. Bone tumors : General Aspects and Data on 6,221 Cases. Illinois : Charles C Thomas, 1981.
9. Hovos AG. Bone tumors : Diagnosis, Treatment and Prognosis. Philadelphia : W.B. Saunders, 1979.
10. Sampatanukul P. Osteochondromas-A retrospective study of 78 cases. *Chula Med J* 1987; 31(7):555-60.

Table 1.

## Cases of osteochondroma with cord compression

Author	Age	Sex	Level	Duration of symptoms	Signs and symptoms	Operation	Result
Reid	30	M	C <sub>2</sub>	7 mos	sensory	None	Death
Ochsner and Rothstein	23	M	C <sub>2</sub>	9 yrs	Motor and sensory	Laminectomy	Slight improvement
Slepian and Hamby	23	M	C <sub>6</sub>	9 mos	Motor and sensory	Laminectomy	Good
Cannon	23	F	T <sub>10</sub>	1 yr	Motor and sensory	Laminectomy	Good
Larson and associates	33	M	T <sub>4</sub>	18 mos	Motor and sensory	Laminectomy	Good
Adam and Morin	24	F	T <sub>4</sub>	3 mos	Motor and sensory	Laminectomy	Not recorded
Decker and Wei	15	M	T <sub>11-12</sub>	1 mo	Motor and sensory	Laminectomy	Good
Carmel and Crammer	13	F	C <sub>2</sub>	4 Mos	Motor and sensory	Laminectomy	Good
Goldenberg and associates	23	M	T <sub>5-6</sub>	1 mo	Motor and sensory	Laminectomy	Good
Vinstein and Franken	14	F	C <sub>2</sub>	3-4 yrs	Motor sensory	Laminectomy	Good
Madigan and associates	7	F	C <sub>2</sub>	2 mos	Motor	Laminectomy	Good
Loftus and associated	28	M	T <sub>4</sub>	5 yrs	Motor and sensory	Laminectomy	Good
Julien and associated	28	F	C <sub>1-2</sub>	4 1/2 yrs	Motor and sensory	Laminectomy	Not recorded
Burr	33	M	T <sub>4</sub>	6 mos	Motor	Laminectomy	Good