

A revisit to the cubital fossa : Brachio-pronatus muscle

Kowit Chaisiwamongkol
Patama Mee-sabye
Somboon SrungBoonmee

*Department of Anatomy, Faculty of Medicine,
Khon Kaen University, Khon Kaen 40002, Thailand.*

Abstract

Surgery of the elbow joints is not uncommon to which several approaches could be made, lateral approach, posterior approach, postero-lateral approach, and medial approach (Anson and McVay, 1971). The detail anatomy of the region is as ever important as the awareness of any of deformity or variation therein. Our experience in Khon Kaen University Medical School dissecting room for 18 years with 288 cadavers supplied us one case of variation in the antecubital fossa. The presence of this superfluous muscle is assessed to interfere with the medial approach of the elbow joint surgery. It was the separate muscle covered with its own fascia and originated from the medial intermuscular septum of the brachium; ran vertically and superficial to the brachial artery and median nerve but deep to the bicipital aponeurosis; and finally joined the pronator teres tendon of insertion. The muscle received branches from the median nerve. We proposed the name "Brachio-pronatus" for this muscle. The name, "Brachial head" of the pronator teres muscle was also suggested by the Society of Anatomy of Thailand member in the 15th Annual Meeting on 22-24 April 1992. Its gross

anatomy will be described and we proposed four possibilities of its developmental anomaly. Its kinesiological advantage is also discussed.

Introduction

It is generally considered that the regularity of any structure of the human body runs between 50-70 percent of the cases (Woodburne, 1965). That leaves 30-50 percent room for variation or deformity that could be found in gross anatomy. This, somehow, reflects the not-so-effective control system of the biological sciences during development compared to the greater regularity in the control observed in the physical sciences. The popular layman statement, "One man's food is another man's poison", is taken here as a combined and eventual result of the variation in the living system which also is demonstrated in gross anatomy.

In answering the question, "Which organ exhibits the greatest frequency of variation?", our fore-runners have collected the data as follow: blood and lymphatic vessels showed the greatest range of variation: bone and tendon showed the least variation while muscles and peripheral nerves took the middle position (Woodburne, 1965).

Does the anatomical variation follow the rule of bilateral symmetry? It was found that one-side variation being twice as frequent as bilateral variation; and the blood vessel variation was more predominant in the right side of the limb (Keen quoted by Woodbure, 1965).

Variations compatible with life may appear not-so-important in the practice of medicine; but its significance is obviously experienced by the thinking surgeons who always look for the unpredictably, non-favourable, anatomical variations. In so doing, the thinking surgeons can save the greater number of patients.

We, therefore, studied and are reporting the case of muscle variation in the cubital fossa.

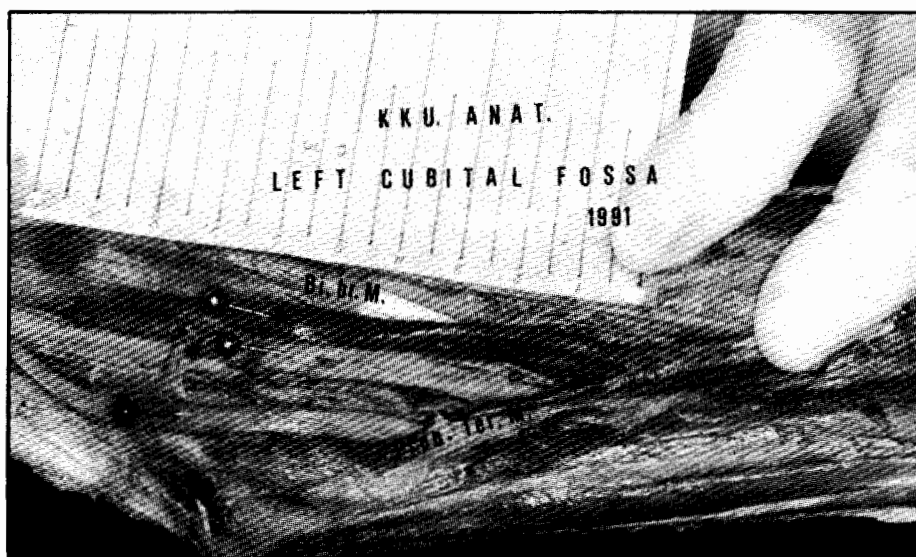Material and Method

We have dissected and/or supervised the dissection of the human bodies amounted to 288 cadavers following the standard dissecting technique handed down by our fore-father

anatomists. One of us have checked all of the cadavers dissected in Khon Kaen University Medical school for 18 years and we found this one case out of 288 in our series.

Result & Discussion

The proposed name for this muscle, Brachio-pronatus, is based on the standard nomenclature. It was found to originate from the medial intermuscular septum in a form of a fibromuscular ribbon about one centimeter wide. It joined the tendon of the pronator teres muscle to the lateral side of the shaft of the radius about its midlength. Its belly is comparable to the size and shape of the pencil, about 13 centimeters long. We dissected out a branch from the median nerve entering the muscle just proximal to the superior boundary of the antecubital fossa. Its arterial supply is from the adjacent brachial artery. Its fascia is characteristically investing the muscle. See the figure below



Left cubital fossa, dissected

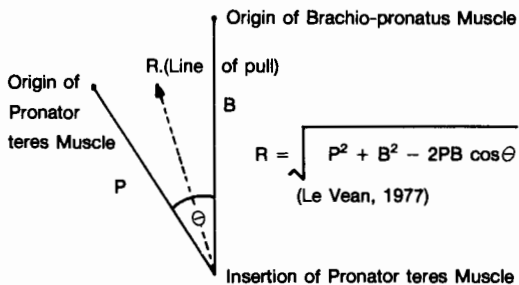
Legends :

green pin = Brachial artery
pink pin? = Brachio-pronatus muscle

red pin = Median nerve
Bi. br. M. = Biceps brachii muscle
Pron. Ter. M. = Pronator teres muscle

Observe a branch from median nerve entering the brachio-pronatus muscle.

Its kinesiology is thought to be beneficial by giving greater force while acting together with the pronator teres muscle as shown below.



such line of pull could also enhance the biceps brachii and brachialis in the elbow flexion. The presence of this muscle, however, may not be so favorable for the orthopedist when making the medial approach to the elbow joints. This muscle is in close contact with the neurovascular bundle from its origin to the apex of antecubital fossa. Its lateral relationship is the biceps brachii in the brachium.

Its relationships in the antecubital fossa are worth mentioning here. It is posterior to the bicipital aponeurosis but anterior to the neurovascular bundle.

This variation falls in the unilateral category which is found more frequently. It is very interesting to note that this cadaver also exhibited a bilateral symmetry of the presence of the extra head of biceps brachii muscle. On the point of view of the developmental history as to why this extramuscle develops in the first place. We have no explanation but we would ascribe this to either 1) a superfluous occurrence of the muscle primordia, or 2) the inaccurate splitting of the primordia, or 3) the normal degeneration of the more-than-necessary parts to become fascia did not take place, or 4) there was a discrepancy in the migration of the muscle primordia. As it receives nerve supply from the median nerve it could have been the primordium of the pronator teres muscle who stopped migrating some what earlier at the upper part.

Conclusion

We found one case of variation out of 288 cadavers in the dissecting room of Khon Kaen University Medical School. It was a muscle with its own fascia and of a pencil morphology about 13 centimeters long and 1 centimeters in diameter. It originated, as a ribbon of one centimeter wide, from the medial intermuscular septum; and ran vertically lateral to the neurovascular bundle to join the distal end of the pronator teres muscle where the two joined the tendon of insertion. Its innervation is from

the median nerve, the blood supply is from the brachial artery. This muscle is between the bicipital aponeurosis superficially and the brachial artery on the deep side in the cubital fossa. We named it, "Brachio-pronatus Muscle" because it possesses such a definite belly that can act almost independently. Though the muscle may have kinesiological advantage for the elbow flexion, it may cause some inconvenience for the medial approach of the joint which is not so favorable for the orthopedists.

As for the developmental history, we proposed four possible courses, namely: superfluous occurrence of the primordia, the inaccurate splitting of its primordium, normal degeneration of the primordium did not take place, and the migration anomaly.

This finding falls in the category of unilateral variation which hitherto predominates the bilateral category.

References:

1. Anson, B.J. and C.B. McVay (1971) Surgical Anatomy 5th Ed. W.B. Saunders Company. Philadelphia. London. Toronto. Igaku shoin LTD. Tokyo.
2. Le Vean, b. (1977) William and Lissner's Biomechanics of Human Motion. pp.15-35. Saunders Company. Philadelphia. London. Toronto.
3. Woodburne, R.T. (1965) Essentials of Human Anatomy. 3rd Ed. Oxford University Press. New York.