

## ความสัมพันธ์ทางกายวิภาคของเส้นเอ็น Palmaris longus และเส้นเอ็น Plantaris

สุรัตน์ เจียรณมงคล<sup>1</sup>, เอกกมล ธรรมโรจน์<sup>1</sup>, วีระชัย โคสุวรรณ<sup>1</sup>, กิมพร ขมะณะรงค์<sup>2</sup>

<sup>1</sup>ภาควิชาออร์โธปิดิกส์

<sup>2</sup>ภาควิชากายวิภาคศาสตร์ คณะแพทยศาสตร์ มหาวิทยาลัยขอนแก่น

## Palmaris longus & Plantaris Tendon: Anatomical Variations & Relationship

Surut Jianmongkol<sup>1</sup>, Ekamol Thumroj<sup>1</sup>, Weerachai Kosuwon<sup>1</sup>, Kimaporn Kamanarong<sup>2</sup>,

<sup>1</sup>Department of Orthopedics,

<sup>2</sup>Department of Anatomy, Faculty of Medicine, Khonkaen University

**Background:** Tendon grafting is the procedure, which often performed in the hand reconstruction. There are many tendons have been used in this procedure for instance palmaris longus, plantaris and toe extensor tendons. Unfortunately, there are many variations in the presence or absence of these tendons. Moreover, the length and diameter of these tendons are also varied from many reports. To determine the length of the tendon, therefore, the length of its corresponding bone could be used.

**Purpose:** To identify the variations of presentation of palmaris longus and plantaris tendons in the cadavers, and to determine the relationship between these two tendons with the length of ulnar and tibial bones.

**Materials and Methods:** Thirty cadavers from the Department of Anatomy were dissected. Palmaris longus and plantaris tendons were identified and measured their lengths and diameters. The length of ulna and tibia were also measured. The data were recorded and analyzed by using Microsoft Excel version program.

**Study design:** descriptive study

**Setting:** Department of Anatomy, Faculty of Medicine, KhonKaen University

**Results:** Eighty percent of the cases had palmaris longus tendon. Twenty percent of the cases had palmaris longus in one side. Ninety-three percent of the cases had plantaris tendons and 6.6% had plantaris tendon in only one side. Of those cases with absent palmaris longus tendon, the plantaris tendon stills present. The mean lengths of palmaris longus were  $14.59 \pm 2.08$  cm. and  $14.24 \pm 2.53$  cm.

**ที่มา:** เส้นเอ็น palmaris longus และเส้นเอ็น plantaris เป็นเส้นเอ็นที่ใช้อยู่ในการผ่าตัดเพื่อ reconstruction ในการผ่าตัดทางมือ แต่มี variation มาก คณะผู้วิจัยจึงได้ทำการศึกษา ความสัมพันธ์ทางกายวิภาคของเส้นเอ็นทั้งสอง กับกระดูก ulna และกระดูก tibia

**วัตถุประสงค์:** เพื่อศึกษาความสัมพันธ์ของเส้นเอ็น palmaris longus และเส้นเอ็น plantaris ในศพอาจารย์ใหญ่ และศึกษาความสัมพันธ์ของเส้นเอ็นทั้งสองกับกระดูก ulna และกระดูก tibia

**วัสดุและวิธีการ:** วัดความยาวและความกว้างของเส้นเอ็น palmaris longus และเส้นเอ็น plantaris ในศพอาจารย์ใหญ่อายุ 30 ศพ รวมทั้งความยาวของกระดูก ulna และกระดูก tibia ที่มีความสัมพันธ์กับเส้นเอ็นทั้งสอง

**ผลการศึกษา:** ในศพอาจารย์ใหญ่อายุ 30 ศพ พบว่า 80 % มีเส้นเอ็น palmaris longus และในจำนวนนี้ 20 % มีเพียงข้างเดียว ส่วนเส้นเอ็น plantaris พบถึง 93% ของจำนวนศพและในจำนวนนี้มี 6.6% ที่มีเพียงข้างเดียว ในศพที่ไม่มีเส้นเอ็น palmaris longus พบว่ายังคงมีเส้นเอ็น plantaris ความยาวเฉลี่ย ของเส้นเอ็น palmaris longus ข้างซ้ายคือ  $14.59 \pm 2.08$  เซนติเมตร และ  $14.24 \pm 2.53$  เซนติเมตรในข้างขวา ส่วนความยาวเฉลี่ยของเส้นเอ็น plantaris คือ  $33.46 \pm 3.09$  เซนติเมตร และ  $31.41 \pm 3.01$  เซนติเมตร ในข้างซ้ายและขวาตามลำดับ ไม่พบว่ามีความสัมพันธ์ระหว่างความยาวของเส้นเอ็นทั้งสองกับกระดูก ulna และกระดูก tibia

**สรุป:** เส้นเอ็น plantaris พบได้มากกว่าเส้นเอ็น palmaris longus และเส้นเอ็นทั้งสองมีความยาวค่อนข้างคงที่ โดยความยาวของกระดูก ulna และกระดูก tibia ไม่มีความสัมพันธ์กับเส้นเอ็นทั้งสอง

on the left and right sides respectively. The mean lengths of plantaris tendon were  $33.46 \pm 3.09$  and  $31.41 \pm 3.01$  on the left and right sides respectively. There was only one case in whom the plantaris tendon width was smaller than 2 mm.. There was no correlation between the lengths of the tendons and the corresponding bones.

**Conclusions:** The palmaris longus tendons seem to be more absent than the plantaris tendon. The length of the ulna could not be determined the length of the palmaris longus tendon and also the length of the tibia could not be determined the length of the plantaris tendons.

ศรีนครินทร์เวชสาร 2545; 17(3), 160-163 • Srinagarind Med J 2002; 17(3), 160-163

## Introduction

In the hand reconstruction, the tendon graft is often used for restoration length or gap of the pathologic tendons. Commonly, palmaris longus is the most frequent tendon to be used. Apart of palmaris longus tendon, plantaris, FDS, EDC of toes are tendons of choice<sup>1</sup> for tendon reconstructions. Palmaris longus and plantaris tendons which are the most frequently used have a lot of variations<sup>2-6</sup>. From the previous studies, palmaris longus was presented in one arm in 85% and absent in 30% of the population<sup>1</sup>. Plantaris tendon was also reported to be presented in 93%.<sup>1</sup> In the people who had no palmaris longus also had no plantaris 2.2%. Moreover 11% of those were found that plantaris was too small (<2 mm. in diameter) to use for the tendon graft.<sup>2</sup> The study of the variation and the relationship between these two tendons and corresponding bones in Thai population still has not been reported. Therefore, the purposes of our study are to report the variation of palmaris longus and plantaris tendons and the relationship of their length, and the length of the corresponding ulna and tibia in the north-eastern Thai people.

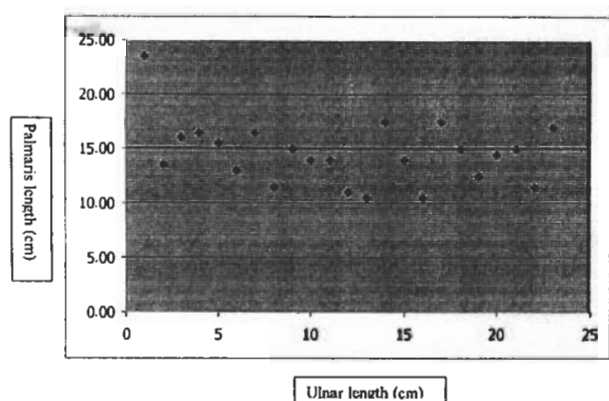
## Materials & methods

Thirty cadavers from the Department of Anatomy, Faculty of Medicine were dissected both sides of the forearms and legs. There were 19 females and 11 males. Average age was 61.50 years old (45 - 72). The height of each cadaver was record in centimeters. The length from the most distal tip of the ulnar styloid to the most proximal tip of the olecranon defined the ulnar length. The tibial

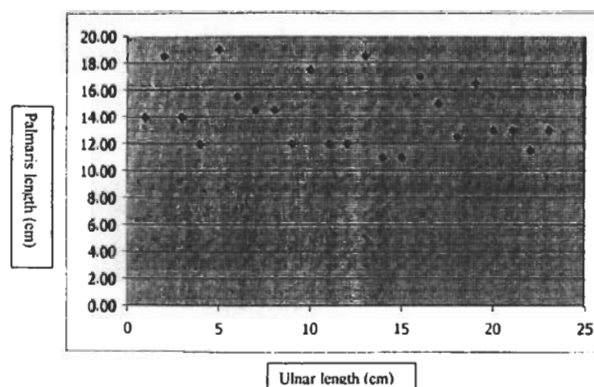
length was defined by the length from the most proximal point of the tibial tuberosity to tip of the medial malleolus. After the dissection was done to identify the palmaris tendon, the distal wrist crease was identified by relocation the skin to the original place. Then the palmaris tendon length was defined by measuring the length between the distal wrist creases to the musculotendinous junction; the muscle length was identified from the musculotendinous junction to the muscle origin. The plantaris tendon length was recorded by measuring the length between the insertion point to the musculotendinous junction; the muscle length was measured from the musculotendinous junction to the muscle origin. The measurements of the length were done by using the measuring tape and width of the tendons in millimeters by the vernia-caliper. Each data was recorded both sides once.

## Results

Eighty percent of the cases (26/30 cases) had palmaris longus tendons. There were 6 cadavers (20%) who had palmaris longus tendon in one. Ninety-three percent of the cases (29/30 cases) had plantaris tendons. Two cadavers (6.6%) had plantaris tendon in one. The case which absence one side of the plantaris tendon, the palmaris longus tendon was also absent on the same side (3.3%). In the case who had no plantaris tendon on both sides, the palmaris longus tendon also absent in one side. In the cases of absence of the palmaris longus tendon on both sides, however, we found that there was no absence of the plantaris tendon.



**Figure 1.** The scattergram between the length of palmaris longus tendon and the ulna bone on the left side.

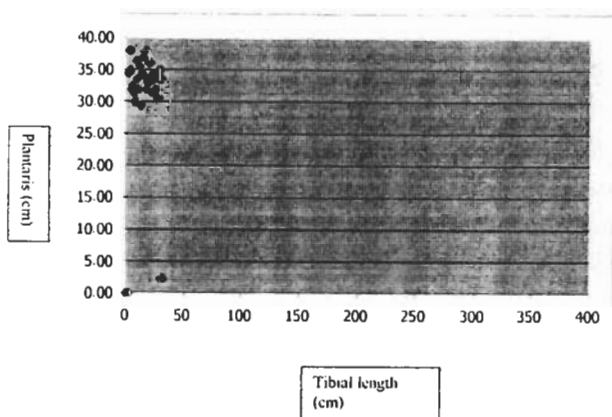


**Figure 2.** The scattergram between the length of the ulna bone and the palmaris longus tendon of the right side.

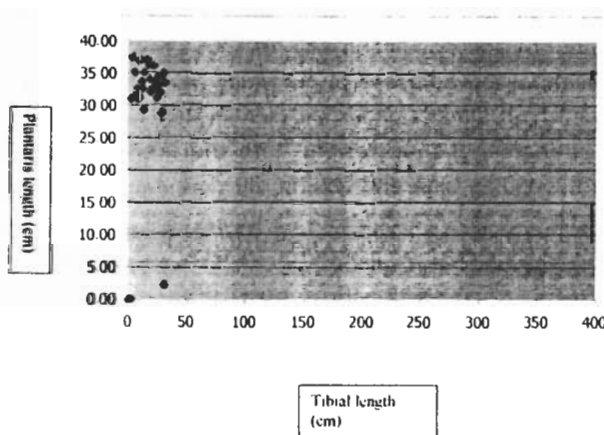
**Table 1.** The lengths (means and standard deviations) of ulna bone, palmaris longus tendon, the palmaris longus muscle, and the width of palmaris longus tendon.

	Ulnar Length (cm)		Palmaris longus length (cm)		Palmaris Muscle length (cm)		Width of Palmaris longus tendon (mm)	
	left	right	left	right	left	right	left	right
mean	25.91	25.76	14.59	14.24	10.83	10.22	4.24	4.23
SD	1.9	1.92	2.92	2.53	2.08	2.33	0.94	0.79

N=30



**Figure 3.** The scattergram between the length of the tibial bone and the plantaris tendon of the left side.



**Figure 4.** The scattergram between the length of the tibial bone and the plantaris tendon of the right side.

There was no correlation between the ulna and the palmaris tendon length (Figure 1 and 2). The mean lengths of the palmaris longus tendon were  $14.59 \pm 2.08$  cm and  $14.24 \pm 2.53$  cm in the left and right sides respectively (Table 1). The ratio between the lengths of the ulna and

the palmaris tendon were  $1.77 \pm 0.35$  and  $1.85 \pm 0.29$  on the left and right sides respectively. The width of palmaris longus tendons were  $4.24 \pm 0.94$  mm and  $4.23 \pm 0.79$  mm on the left and right sides respectively.

There was no correlation between the tibia and

**Table 2.** The lengths (means and standard deviations) of tibial bone, plantaris tendon, the plantaris muscle, and the width of plantaris tendon.

	tibial length (cm)		palmaris tendon length (cm)		palmaris muscle length (cm)		palmaris tendon width (mm)	
	left	right	left	right	left	right	left	right
mean	33.66	33.46	31.09	31.41	7.82	7.50	3.06	3.19
SD	2.24	2.33	3.09	3.01	1.34	1.52	1.06	1.02

N=30

plantaris tendon length (Figure 3 and 4). The mean lengths of the plantaris tendon were  $31.09 \pm 3.09$  cm and  $31.41 \pm 3.01$  cm on the left and right sides respectively (Table 2). The ratios between the tibia and the plantaris tendon lengths were  $1.09 \pm 0.09$  on the left side and  $1.07 \pm 0.07$  on the right. The widths of plantaris tendon were  $3.06 \pm 1.06$  mm and  $3.19 \pm 1.02$  mm on the left and right sides respectively.

### Discussions

From the previous studies, there were many variations of the presence of palmaris longus tendon<sup>2-6</sup>. In our study, we found that the absence or unilateral presentation of palmaris longus tendon was less incidence than the previous report<sup>1</sup>. Plantaris tendon was reported to be presented in 93%<sup>1</sup> of the population which was nearly the incidence of our study. Regarding Vanderhoof's study, 2.2% of the population who had no palmaris longus, would have no plantaris tendon either. This was different from our findings, we did not find any absence of both tendons in our study. Moreover, he also found that eleven percent of the plantaris tendon was too small (<2 mm.) to use for the tendon graft.<sup>2</sup> However, in our study, there was only one case in whom the plantaris tendon was smaller than 2 mm in diameter.

The relationship of the palmaris longus and the ulnar length has not been mentioned before, however, there were no relationship between the lengths of the tendon and the ulna. Therefore, we concluded that we could not use the

length of the ulna for determination of the length of the particular tendon. The tendon had less variation in its length. The plantaris tendon and tibial length, we found that there was either no correlation.

In conclusion; plantaris tendon is more frequently found than palmaris tendon and its length is longer. Therefore, plantaris tendon should be the tendon of choice for hand reconstruction or in the case that need the long tendon graft length. Moreover, the length of the ulna and tibia cannot be used as a predictor for the length of both palmaris longus and plantaris tendons in orderly.

### References

1. Wright PE. Flexor and extensor tendon injuries. In: Canale S.T., ed. Campbell's Operative Orthopedics. St. Louis : Mosby, 1998:
2. Vanderhoof E. The frequency of and relationship between the palmaris longus and plantaris tendons. Am J Orthop 1996; 25(1):38-41.
3. Wehbe MA. Tendon graft donor sites. J Hand Surg[Am] 1992;17(6):1130-2.
4. Zeybek A, Gurunluoglu R, Cavdar S, Bayramicli M. A clinical reminder: a palmaris longus muscle variation. Ann Plast Surg 1998; 41(2):224-5.
5. Carlson GD, Botte MJ, Josephs MS, Newton PO, Davis JL, Woo SL. Morphologic and biomechanical comparison of tendons used as free grafts. J Hand Surg[Am] 1993;18(1): 76-82.
6. Koo CC, Roberts AH. The palmaris longus tendon, another variation in its anatomy. J Hand Surg[Br] 1997;22(1):138-9.

SMJ