

Histochemical Detection of Glycoconjugates in Colonic Epithelium of the Goat

Pakawadee Pongket¹, Suppalak Romrattanapun²,
Maleewan Liumsiricharoen¹, Dollada Srisai¹ and Apinun Suprasert¹

ABSTRACT

The distribution of glycoconjugates in the goat descending colon was studied by means of light microscopic histochemical methods. The staining procedures employed were horseradish peroxidase conjugated lectin, alcian blue (AB) pH 2.5, periodic acid-Schiff (PAS), ABpH 2.5-PAS, high iron diamine (HID), HID-ABpH 2.5. The lectins used in the present study were concanavalin A (ConA), *Ricinus communis* agglutinin I(RCA-I), *Solanum tuberosum* agglutinin (STL) and *Limulus polyphemus* agglutinin(LPA). The result revealed that descending colonic epithelium of the goat contained acid sulfated glycoconjugates and neutral glycoconjugates with α -D-mannose, α -D-glucose, β -D-galactose, N-acetylglucosamine and sialic acid residues. The quantity of neutral glycoconjugates with α -D-mannose, α -D-glucose, β -D-galactose and N-acetylglucosamine increased from mucosal crypt up to mucosal surface of the epithelium, while sialic acid residues and sulfated glycoconjugates decreased from mucosal crypt to mucosal surface.

Key words: histochemistry, glycoconjugate, colon, goat

INTRODUCTION

One of the main function of the gastrointestinal epithelium is the production of the protective and lubricant mucus. Such mucus has been shown to be biochemically and a heterologous entity being composed of high molecular weight glycoconjugates. Previous histochemical studies have revealed that the secretory glycoconjugates of the gastrointestinal tract are varied in property from species to species, in addition to regional variations within a particular species (Sheahan and Jervis, 1976; Freeman *et al.*, 1980). In different mammals, furthermore, a series of histology and biochemistry has so far been made on glycoconjugates involved in the colonic epithelium and a wealth of information

is available (Sheahan and Jervis, 1976; Thomopolous *et al.*, 1983). However, glycoconjugates histochemical studies of the goat epithelium have been reported only with conventional method. The present study was designed to clarify glycoconjugates components in the goat colon by using currently available methods of lectins and correlated procedures.

MATERIALS AND METHODS

Goats of different ages and sexes were sacrificed by exsanguination under deep anesthesia. Tissue material from middle part of descending colon was dissected out and fixed immediately by immersion in 10% formaline containing 2% calcium acetate for 24 hrs. at 4°C After that the tissue

¹ Department of Anatomy, Faculty of Veterinary Medicine, Kasetsart University, Bangkok 10900, Thailand

² Department of Zoology, Faculty of Science, Kasetsart University, Bangkok 10900, Thailand

samples were processed routinely for embedding in paraplast and sectioned serially at 3 μ m. in thickness. The tissue sections were then subjected to stain with the following staining procedures.

Conventional staining procedures

1. Haematoxylin and eosin for the general observation of histological structures.
2. AB pH 2.5 for acidic glycoconjugates (Spicer, 1960)
3. Periodic acid-Schiff (PAS) for vicinal diol containing glycoconjugates (Pearse, 1968)
4. AB pH 2.5-PAS for demonstrating of acidic and neutral glycoconjugates (Spicer *et al.*, 1967)
5. High iron diamine (HID) for sulfated glycoconjugates (Lev and Spicer, 1964)
6. HID-AB pH 2.5 for demonstrating of sulfated glycoconjugates and carboxylated glycoconjugates (Spicer *et al.*, 1967)

Lectin staining procedures

Briefly, deparaffinized sections were treated with 1% bovine serum albumin (BSA) in 10 mM phosphate buffer saline (PBS) pH 7.4 and then incubated with biotinyl lectins (25 μ g/ml, Vector Lab Inc. USA) in 0.1% BSA-PBS for 30 min. After rinsing with PBS, the sections were incubated in avidin-biotinyl peroxidase complex (ABC Vector lab Inc. USA) for 30 min. rinsed with distilled water, dehydrated and mounted.

The lectins use in this study, along with their

reported carbohydrate binding specificities are listed in table 1.

Control experiments

For lectin staining, control procedures were performed : Tissue sections were preincubated in appropriated hapten sugars for each lectin and then incubated in lectin solutions containing hapten sugars, non specific staining was also checked by incubation in the ABC and DAB-H₂O₂ solutions.

RESULTS

The results of the stainings are summarized in Table 2

The mucosal surface and crypts of the goat descending colon are lined with simple columnar epithelium. The epithelium in the crypts consists mainly of goblet cells whereas absorptive columnar cells and some goblet cells occur in the upper half of the crypts and the mucosal surface. When the epithelium was reacted with PAS, mucous granules of goblet cells and striated border of columnar cells stained moderately at lower crypts and stained intensely at the mucosal surface. By AB pH 2.5 staining, mucous granules of goblet cells and striated border of columnar cells were moderate to deep blue. When the colonic epithelium was reacted with AB pH 2.5-PAS, both structures at lower crypts were blue or red while those in mucosal surface were deep purple. (Fig. 1) The HID procedure resulted in strong positive reaction in the two

Table 1 List of lectins employed histochemical studies and their binding specificities according to references cited.

Lectins binding	Specificities	References
Concanavalin A	α -D-Man., α -D-glu.	Kiernan, 1975
<i>Ricinus communis</i> RCA-I	β -D-gal	Yamada and Shimizu, 1977
<i>Solanum tuberosum</i> STL	β -D-GlcNAc	Goldstein and Hayes, 1978
<i>Limulus polyphemus</i> LPA	NeuAc	Goldstein and Hayes, 1978

structures. When stained with the HID-ABpH2.5 sequence, the surface goblet cells and crypt goblet cells turned to a mixture of black and blue coloration.

The mucous granules of goblet cells and striated border of columnar cells in the colonic epithelium reacted strongly with ConA (Fig. 2), RCA-I and STL. Both the Con A and RCA-I staining of goblet cells and striated border of columnar cells increased in intensity with the upward cell migration along the crypts. Only mucous granules of goblet cells and striated border of columnar cells at the lower crypts showed affinity against LPA while those at mucosal surface showed negative stain.

DISCUSSION

The precise identification of glycoconjugates and their localization when correlated with changes in morphogenesis, tumorigenesis and physiological

function may help us to understand valuable agents for the demonstration of various saccharide residues. Using biotinyl lectins we examined the distribution of glycoconjugates in the goat descending colon by light microscopic histochemical methods.

In the present study we find the different distribution of glycoconjugates between the mucosal crypt and mucosa surface of the goat colon. PAS is believed to stain sugars with vicinal diol group and neutral charges including β -D-galactose, α -D-mannose, α -D-glucose and N-acetyl derivatives of the hexosamines while AB pH 2.5 stains the carboxyl groups of sialic glycoconjugates or other glycoconjugates with a strong negative charge (Spicer *et al.*, 1967). Pattern of staining for acid and neutral glycoconjugates with PAS at the mucosal surface correlate well with our finding that lectins which recognize these residues (ConA, RCA-I) stain this region moderately to poorly. Alcian blue stains

Table 2 Histochemical reactions of glycoconjugates in the goat colonic epithelium.

Staining procedures	Mucosal crypt		Mucosal surface	
	Crypt goblet cells	Striated border of columnar cells	Surface goblet cells	Striated border of columnar cells
AB pH 2.5	2-3 B	2B	3 B	1-2B
PAS	2M	1-2M	3-4 M	2-3M
ABpH 2.5-PAS	2BM	2 BM	3MB	2BM
HID	3BL	2 BL	2BL	3BL
HID-ABpH2.5	3BLB	2 BLB	2BBL	2B
ConA	1-2 Br	2 Br	3 Br	1Br
RCA-I	1-2 Br	2 Br	3Br	2-3Br
STL	2 Br	2 Br	3Br	3Br
LPA	1-2 Br	1-2 Br	0	0

Key to symbols in table

B : AB positive , M : PAS positive , BL : HID positive , Br : Lectin positive

MB : A mixture of PAS and AB-positive glycoconjugates with PAS positive glycoconjugates predominating.

BM : A mixture of AB-and PAS-positive glycoconjugates with AB positive glycoconjugates predominating

BLB : A mixture of HID and AB-positive glycoconjugates with HID positive glycoconjugates predominating

BBL : A mixture of AB and HID-positive glycoconjugates with AB positive glycoconjugates predominating

0 : Negative reaction

1-3 : Numerical values correspond to increasing intensity of staining

glycoconjugates throughout the colon suggesting the presence of acid mucins in all of these segments. The absence of staining by LPA in the mucosal surface suggests that the acid mucins recognized by AB are probably not sialomucins and may represent sulfated residues or proteoglycans.

In view of the staining specificities of the AB pH 2.5, PAS, AB pH.2.5-PAS, HID, HID-ABpH 2.5 (Spicer *et al.*,1967) the present results

can be comprehended consistently in the goblet cell colonic epithelium, glycoconjugates are provided primarily with acid sulfated and vicinal diol groupings. However the glycoconjugates in the villus epithelium appear to be higher in acidity as compared with those in the crypt epithelium.

If the staining mechanisms underlying the positive staining reaction of Con A,RCA-I and STL at the mucous granules of goblet cells and striated

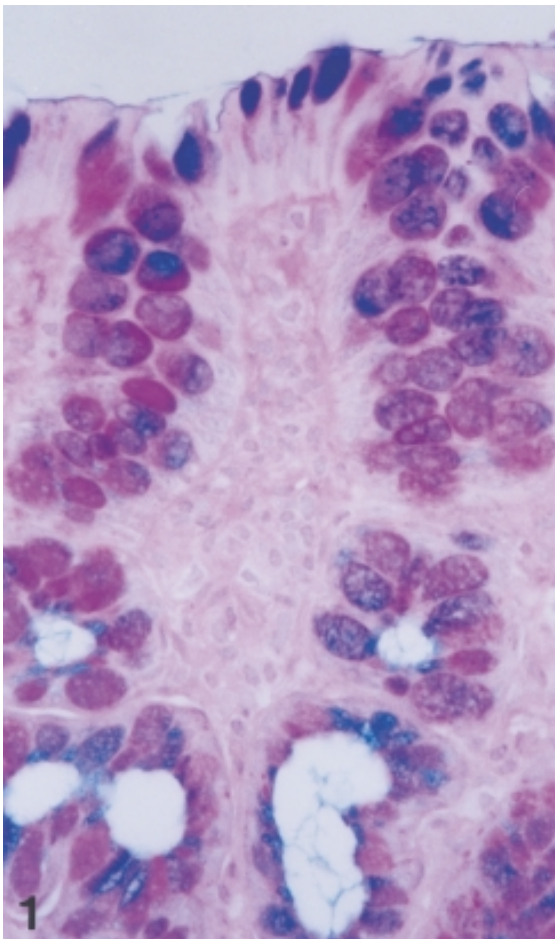


Figure 1 The dual staining with ABpH2.5-PAS result in blue or red at crypt goblet cells but stain deep purple or primarily blue at surface goblet cells. X260

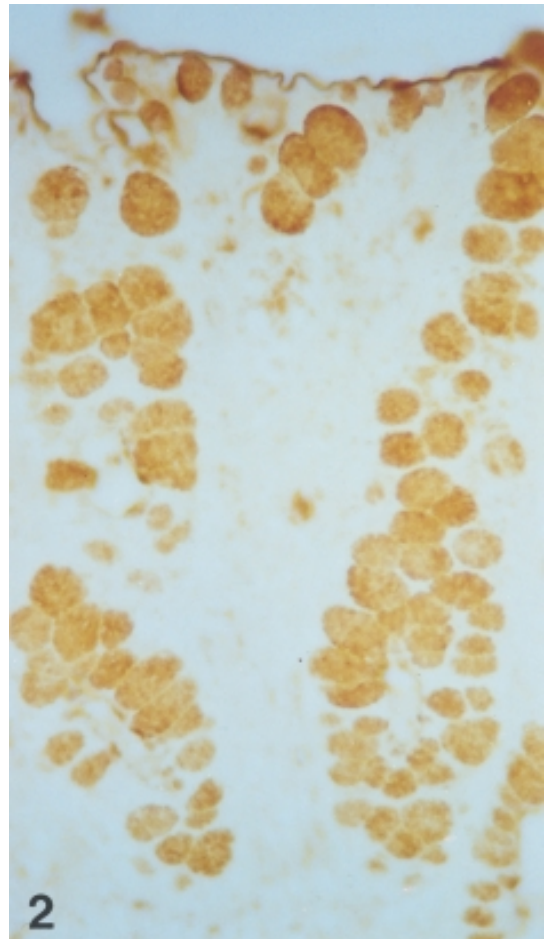


Figure 2 Mucous granules of goblet cells exhibit strong to moderate positive reaction. However the positive reactions of mucous granules of goblet cells at the surface are stronger in intensity than those at the crypt Con A. staining. X260

border of columnar cells are taken into consideration; the present conclusion can be made : carbohydrates in the epithelial cells of the goat colon are glycoconjugates with α -D-glucose, α -D-mannose, β -D-galactose and N-acetylglucosamine. In addition, glycoconjugates with terminal sialic acid residues were also present in the goblet cells mucous granules at mucosal crypt as judged from their positive staining with LPA.

In a similar way to that described in many mammalian species, the epithelial cells of the goat colon contain both sialomucin and sulfomucins. Such acid glycoconjugates may play an important role in resisting the invasion of potential pathogens (Schauer, 1982). Sialic acid and sulfated groups are also believed to play an essential role of lubrication and protection of digestive tract (Werner *et al.*, 1982). Functional activities of other sugar residues of glycoconjugates are still unknown.

LITERATURE CITED

- Freeman, H.J., R. Lotan, and Y.S. Kim. 1980. Application of lectin for detection of goblet cell glycoconjugates differences in proximal and distal colon of the rat. *Lab. Invest.* 42 : 405-412.
- Goldstein, I.J., and C.E. Hayes. 1978. The lectins : Carbohydrate-binding proteins of plants and Animal. *Adv. Carbohydr. Chem. Biochem.* 35 : 127-340.
- Kiernan, J.A. 1975. Localization of α -D-glucosyl and α -D-mannosyl groups mucosubstances with concanavalin A and horseradish peroxidase. *Histochemistry* 44 : 39-45.
- Lev, R., and S.S. Spicer. 1964. Specific staining of sulphate groups with alcian blue at low pH. *J. Histochem. Cytochem.* 12 : 309.
- Pearse, A.G.E. 1968. The periodic acid-Schiff technique, pp. 659-660. *In* Histochemistry. Theoretical and applied. Vol 1. 3rd ed. J and A Churchill, Edinburgh.
- Schauer, R. 1982. Chemistry, metabolism and biological functions of sialic acid. *Adv. Carbohydr. Chem. Biochem.* 40 : 131-234.
- Sheahan, D.G. and H.R. Jervis. 1976. Comparative histochemistry of gastrointestinal mucosubstances. *Am. J. Anat.* 146 : 103-132.
- Spicer, S.S. 1960. A correlative study of the histochemical properties of rodent acid mucopoly-saccharides. *J. Histochem. Cytochem.* 8 : 18-36.
- Spicer, S.S., R.G. Horn, and T.J. Leppi. 1967. Histochemistry of connective tissue mucopoly saccharides, pp. 251-303. *In* B.M. Wagner and D.E. Smith (eds.). *The connective tissue.* Williams & Wilkins, Baltimore.
- Thomopolous, G.N., B.A. Schulte, and S.S. Spicer. 1983. Light and electron microscopic cytochemistry of glycoconjugates in the rectosigmoid colonic epithelium of the mouse and rat. *Am. J. Anat.* 168 : 239-256.
- Yamada, K. and S. Shimizu. 1977. The histochemistry of galactose residues of complex carbohydrates as studied by peroxidase-labeled Ricinus communis agglutinin. *Histochem.* 53 : 143-156.
- Werner, R., K. Eckart, B. Christian, and G. Wolfgang. 1982. Biological significance of sialic acid, pp. 263-305. *In* R. Schauer (ed.) *Sialic acid : Chemistry, Metabolism and Function, Cell Biology Monograph.* Vol 10 Springer Verlag, Wien, New York.

Received date : 20/02/01

Accepted date : 29/06/01