

## รูปแบบการชักนำการเกิดแผลภายนอกในร่างกายสัตว์ทดลอง: การทบทวนวรรณกรรม

### Induction of External Infection-models in Experimental Animals: A review

นิธิตา ตติยาภิริดี<sup>1,2</sup>, วรัญญา จตุพรประเสริฐ<sup>2,3</sup>, กนกวรรณ จารุกัจฉา<sup>2,4\*</sup>

Nitima Tatiya-aphiradee<sup>1,2</sup>, Waranya Chatuphonprasert<sup>2,3</sup>, Kanokwan Jarukamjorn<sup>2,4\*</sup>

Received: February 2015 ; Accepted: May 2015

#### บทคัดย่อ

โรคติดเชื้อเป็นสาเหตุสำคัญหนึ่งของการสูญเสียชีวิต รวมไปถึงผลกระทบต่อภาวะทางเศรษฐกิจ การคิดค้นหรือพัฒนายาใหม่เพื่อจัดการกับการติดเชื้อเหล่านี้จึงเป็นสิ่งจำเป็น การทดสอบประสิทธิภาพของสารต้านเชื้อในหลอดทดลองสามารถบ่งบอกศักยภาพเบื้องต้นของสารทดสอบ แต่การยืนยันประสิทธิภาพและประสิทธิผลที่แท้จริงจำเป็นต้องทำการศึกษาในสัตว์ทดลอง การทบทวนวรรณกรรมนี้มีวัตถุประสงค์เพื่อรวบรวมวิธีการชักนำให้เกิดแผลที่ผิวหนังหรือภายนอกในร่างกายของสัตว์ทดลอง โดยแต่ละประเภทยังมีความแตกต่างกันตามหลักการการทำให้เกิดบาดแผล ชนิดของเครื่องมือที่ใช้ทำให้เกิดแผล และลักษณะของบาดแผล ตลอดจนสายพันธุ์ของสัตว์ทดลองและเชื้อจุลินทรีย์ที่สนใจศึกษา โดยสามารถแบ่งได้ 5 ประเภทตามหลักการการชักนำให้เกิดแผล ได้แก่ skin abrasion infection model, burn wound infection model, foreign body infection model, lacerated wound infection model และ excisional wound infection model ดังนั้น การเลือกใช้วิธีการชักนำการเกิดแผลจึงขึ้นอยู่กับการศึกษาของผู้ศึกษาให้สอดคล้องกับวัตถุประสงค์ของงานวิจัยเพื่อให้สามารถนำข้อมูลการศึกษาไปประยุกต์ใช้ได้จริงต่อไป

**คำสำคัญ:** การติดเชื้อภายนอก สัตว์ทดลองตัวแบบ การทดลองในสัตว์ทดลอง แผล

#### Abstract

Infection remains a leading cause of mortality and economic loss. Development of a new effective antimicrobial agent to combat infection is necessary. *In vitro* testing is investigated for basic potential, but it is insufficient to assure efficiency and efficacy of an antimicrobial agent. Hence, *in vivo* testing has been recognized as the essential study to provide reliable information and to support the *in vitro* data. This review aims to summarize models for the induction of external infections in experimental animals and categorize by the principles and equipment of the wound inductions, appearance of the wounds, and strains and species of animals, and microorganisms employed. The induction of external infection models in animals is divided into 5 categories including skin abrasion infection model, burn wound infection model, foreign body infection model, lacerated wound infection model and excisional wound infection model. Thus, the optimal wound induction model depends on the aim(s) of a study and consideration criteria of a researcher to gain the informative and applicable data.

**Keywords:** external infection, animal model, *in vivo*, wound

<sup>1</sup> นักศึกษาปริญญาโท หลักสูตรวิทยาศาสตร์มหาบัณฑิต, สาขาเภสัชเคมีและผลิตภัณฑ์ธรรมชาติ, คณะเภสัชศาสตร์ มหาวิทยาลัยขอนแก่น จ.ขอนแก่น 40002

<sup>2</sup> กลุ่มวิจัยฤทธิ์ทางยาของผลิตภัณฑ์ธรรมชาติโดยเทคโนโลยีชีวภาพทางเภสัชศาสตร์ (PANPB), คณะเภสัชศาสตร์ มหาวิทยาลัยขอนแก่น

<sup>3</sup> อาจารย์, คณะแพทยศาสตร์ มหาวิทยาลัยมหาสารคาม จ.มหาสารคาม 44150

<sup>4</sup> รองศาสตราจารย์, สาขาวิชาเภสัชเคมี คณะเภสัชศาสตร์ มหาวิทยาลัยขอนแก่น จ.ขอนแก่น 40002

\* Corresponding author : E-MAIL: kanok\_ja@kku.ac.th; Phone/Fax: +66 43 202 305/+66 43 202 379

<sup>1</sup> Candidate in Master degree of Sciences in Pharmaceutical Chemistry and Natural Products, Faculty of Pharmaceutical Sciences, Khon Kaen University, Khon Kaen 40002 Thailand

<sup>2</sup> Research Group for Pharmaceutical Activities of Natural Products using Pharmaceutical Biotechnology (PANPB), Faculty of Pharmaceutical Sciences, National Research University-Khon Kaen University, Khon Kaen 40002 Thailand

<sup>3</sup> Lecturer, Faculty of Medicine, Mahasarakham University, Mahasarakham 44150 Thailand

<sup>4</sup> Associate Professor, Division of Pharmaceutical Chemistry, Faculty of Pharmaceutical Sciences, Khon Kaen University 40002 Thailand

## Introduction

Despite intensive research over past decades, infection remains a leading cause of illness and disease.<sup>1</sup> From then to the present, researchers have done many investigations to seek an effective antimicrobial agent against infection. Using only *in vitro* testing is insufficient to confirm the effectiveness and efficacy of an antimicrobial agent. *In vivo* testing has become to be recognized as the essential study to provide reliable information and to support the *in vitro* data. The host-pathogen relationship and the complexity of the immune response to infection remain to be learned in order to develop a new therapy. Animal models have become standard tools for the study of external wound infections.<sup>2</sup> An experimental animal model is an important tool to assess the efficiency of an antimicrobial agent before the extensive studies are further performed in the clinical trial. Herewith, several methods to induce external infections in animals are critically reviewed. The animal infection models can be divided into 5 categories including 1) skin abrasion infection model, 2) burn wound infection model, 3) foreign body infection model, 4) lacerated wound infection model, and 5) excisional wound infection model. Five categories are divided by appearance or characteristics of the wounds. The review is informative and useful for a researcher in the related field to apply the appropriate or optimal method to induce the external infection in an animal correlated to the aim(s) of the study.


## Skin abrasion infection model

Skin abrasion is a wound that bruised or scratched off skin which can occur on any part of body. The wound is often contaminated from the environment and can develop into a severe lesion. Skin abrasion is the most common infection occur in the superficial skin including epidermis and upper layer of dermis. This model compiles 5 methods depending on the types of instruments to introduce the abraded wound including 1) tape stripping model, 2) needle scratch model, 3) blade scratch model, 4) sand surface model, and 5) dermatome model as follows.

## Tape stripping model

Fur is stripped from an anesthetized adult female BALB/c mouse by an elastic adhesive bandage (Tensoplast®) in the area of 2 cm<sup>2</sup> for 7-10 times until the skin becomes red and glisten. Regular bleeding was not observed. The method results in removal of most of the epidermis. Some basal epidermal cells remain. The skin was measured for transepidermal water loss (TEWL) by a DermaLab TEWL probe (Cortex Technology, Hadsund, Denmark) to reach approx. 70 g/m<sup>2</sup>h before applying a 5-μl bacterial suspension (10<sup>7</sup> cells of *Staphylococcus aureus* FDA846) onto the skin. For analysis, a 2 cm<sup>2</sup>-wound was excised and homogenized in PBS (phosphate-buffered saline), and then the homogenates were plated in agar to evaluate the bacterial numbers (CFU) after the inoculation for 4 h.<sup>3</sup>

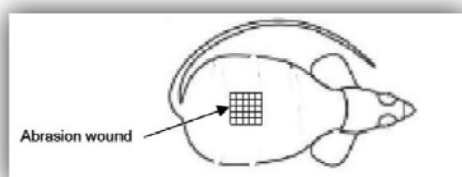
In the study of Pastagia et al.<sup>4</sup> the tape stripping infection was performed according to the approach of Kugelberg et al.<sup>3</sup> with some modifications. An anesthetized adult female BALB/c mouse was shaved with an electric razor on the 2 cm<sup>2</sup>-dorsum. Autoclave tape was used to strip the shaved area for approx. 15-20 times in succession and using a fresh piece of tape each time. The stripped skin visually shows reddening because of epidermis removal (Figure 1). TEWL was measured to standardize degree of irritation using VapoMeter instrument (Delfin Technologies, Kuopio, Finland). The result of shaved and tape-stripped skin was 75 g/m<sup>2</sup>h, on average. To grade the degree of inflammation, H&E stained skin section was prepared. A 5 μl-bacterial suspension containing 10<sup>7</sup> cells of *S. aureus* was applied on the tape-stripped skin. After 4 h of the infection, the infected area was excised and homogenized for colony-counting.



**Figure 1** Tape-stripped area<sup>4</sup>

### Needle scratch model<sup>5</sup>

An adult female BALB/c mouse was administered two doses of cyclophosphamide to reduce peripheral blood neutrophils to less than 100/ml blood for fostering a more vulnerable environment in the mouse to infection. The first dose at 150 mg/kg was intraperitoneally injected at 4 d before the infection and the second dose at 100 mg/kg was done at 1 d before the infection. The mouse was anesthetized before making skin abrasion wounds by 28-gauge needles. The 6×6 crossed scratch lines within a defined 1×1 cm<sup>2</sup>-area were created on the dorsal surfaces (Figure 2). The stratum corneum and upper layer of the epidermis are damaged but not the dermis. An aliquot of 50 µl-bacterial suspension containing 10<sup>8</sup> CFU methicillin-resistant *S. aureus* (MRSA) was exposed to the wound. The skin photograph was taken by bioluminescence images after the inoculation using an ICCD photon-counting camera.

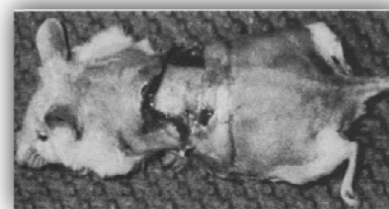

**Figure 2** Appearance of needle scratch diagram<sup>5</sup>

### Blade scratch model

An adult male CF-1 mouse was used for superficial cutaneous bacterial infections by blade scraping.<sup>6</sup> Four days before challenging microorganism, the mouse was intraperitoneally injected with cyclophosphamide at doses ranged from 0 to 150 mg/kg for immunosuppression. The mouse was anesthetized with pentobarbital sodium at a dose of 75 mg/kg before the infection. Fur was shaved and the remaining hair depilated using hair removal cream. On the following day, the mouse is anesthetized again before superficial wounding. The skin is shaved by scraping with a no. 24-scalpel blade until the skin become reddening. One drop (0.02 ml) of bacterial suspension containing 10<sup>5</sup> CFU (*S. aureus*, *S. saprophyticus*, *S. epidermidis*, or *Micrococcus luteus*) was applied to the wound. The wound site (approx. 10 mm<sup>2</sup>) was covered with

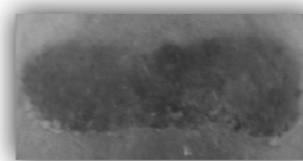
a sterile plastic film (15-mm<sup>2</sup>) and secured with a surgical tape to limit removal of the occlusive dressing. The dressing was removed at the indicated day to examine white-gray abscesses (Figure 3). Semi-quantitative bacterial analysis of the wound site was done by the modified technique of Leyden et al.<sup>7</sup> In brief, the trypticase soy agar is used to aerobically incubate for 48 h at 37°C. Bacterial counts were expressed as CFU per site. Eighty-nine percent of the mice developed large abscesses (15 mm-diameters) at the dose of 50 mg/kg cyclophosphamide and the inoculum of 10<sup>5</sup> CFU.



**Figure 3** Abscess formation at day 6 of after *S. aureus* Mi271 inoculation<sup>6</sup>

### Sand surface model

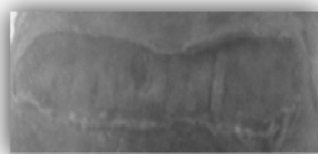After anesthetization, the hairless SKH1 was prepared to perform a partial-thickness wound. The rotary tool with a sterile sanding attachment was repeatedly touching the back.<sup>8</sup> The skin and tissue become red and glistening (Figure 4).



**Figure 4** Photograph at dorsal of the back after wounding<sup>8</sup>

After wounding, the skin was cleaned tenderly. Bacterial suspension (2×10<sup>7</sup> CFU) of MRSA strain ATCC 33592 was inoculated on the wound. Moistened bandage with saline was dressed to maintain a moist wound. After 24 h, the wound-surface was visibly changed (Figure 5).

The nature of the infection was examined by quantitative microscopy and microbiology. The wound biopsy samples were performed. Bacterial counts were at 4 h after the inoculation.



**Figure 5** Wound surface at 24 hours after MRSA inoculated with MRSA for<sup>8</sup>

### Burn wound infection model

The burn wound infection is categorized by a different heating source including gas flame, ethanol burn, boiling water, preheated single metal bar, and preheated double brass block. The wound location is usually located on the shaved back. To induce infection, bacterial suspension is topically applied on the wound or subcutaneously injected.

### Gas flame burn model

Pathogenesis of MRSA<sup>9</sup> or *Enterococcus faecalis* translocation<sup>10</sup> in immunodeficient mice with thermal injury was performed using a gas flame burn model. Seven to eight weeks old SCIDbg mouse (Severe combined immunodeficiency beige mouse) is anesthetized and the back is shaved from groin to axilla. An insulated mold (with a 2.5×3.5 cm<sup>2</sup>-window) was pressed firmly on the skin. The opening area was exposed to the gas flame for 9 s by a Bunsen burner. The 15% total body surface area burned by this procedure was in the third degree. After the thermal injury, a 1 ml-saline was intraperitoneally injected for fluid resuscitation. The MRSA (2×10<sup>3</sup> CFU/mouse) was applied on the wound at the day 2 after being injured. The mean survival time in days and the survival percentage at 7 d after the infection were the criteria to evaluate the infection.

### Ethanol burn model

This model was employed to study the pathogenesis of *P. aeruginosa*<sup>11,12</sup> and *Klebsiella pneumoniae*,<sup>13</sup> including the local delivery of polyclonal immunoglobulin against the burn infection.<sup>14</sup> An adult female CF1 mouse was anesthetized and the back is shaved. An asbestos board with an opening 30% of total body surface area

was pressed onto the skin. Ethanol was spread on the exposed skin and ignited, then leaved for 10 s to allow burning. The inoculum (100 CFU of *P. aeruginosa*) was subcutaneously injected to the burned area which exposed with ethanol. After 20 h of the infection, the mouse appears moribund.

### Boiling water burn model

Rumbaugh et al.<sup>15</sup> and McVay et al.<sup>16</sup> performed the modified burned mouse model of Steritz and Holder.<sup>11</sup> An adult female ND4 Swiss Webster mouse was anesthetized. The back is shaved and uncovered by placing into the template with an opening 4.5×1.8 cm<sup>2</sup>. About 15% total body surface area of the mouse was exposed to 90°C water for 10 s through a template to injure the full-thickness skin. This injury was nonlethal. A 0.8 ml of 0.9% NaCl solution is subcutaneously injected to the burn as fluid replacement therapy. A 100 µl of bacteria suspension (2-3×10<sup>2</sup> CFU of *P. aeruginosa*) is subcutaneously injected directly under the burn skin or a 100 µl of sterile PBS for the control mouse. Mortality of the mouse is monitored for 4-5 d after the inoculation. The mouse was killed at 96 h-post-infection and the internal organs are weighed and homogenized.

### Preheated single metal bar burn model

Orenstein et al.<sup>17</sup> developed a preheated single metal bar burn model. A guinea pig was anesthetized and the back is shaved and depilated. A copper plate of 1×1×3 cm<sup>3</sup> equipped with a handle was heated to 150°C. The heated plate is placed on the skin for 10 s. This procedure results in the third degree burn. After the burning for 15 min, a 1 ml-*S. aureus* suspension (containing 10<sup>8</sup> cells/ml) is smeared on the wound. The burned surface was wrapped by a gauze pad. After the infection for 24 h, the bacterial count in the untreated burns was reached 2×10<sup>9</sup> CFU/g eschar.

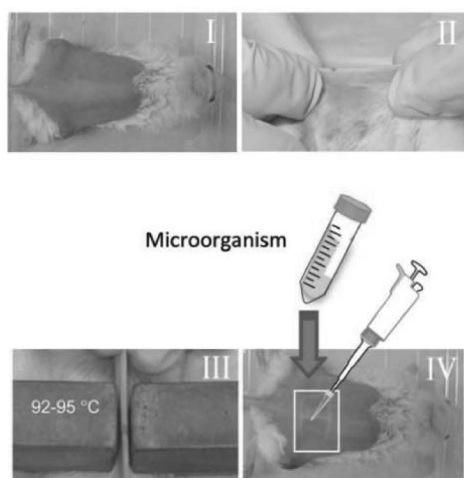
### Preheated double brass block burn model

Stevens<sup>18</sup> performed a preheated double brass block. An adult CD1 mouse was anesthetized and shaved on the back. The two pre-heated brass blocks (92–95°C)

are applied to the opposing sides of the elevated skin folder on the back for 5 s, corresponding to 5% total body surface area. After the burning, *P. aeruginosa* ( $10\text{--}10^6$  CFU) was intradermally injected to the wound (Figure 6). Ten days after the inoculation, the survival rate was 60%. This model was employed with some modifications in order to assess the potency of antimicrobial photodynamic therapy (PDT) and chitosan acetate bandage for the burn infection.<sup>20,21,22</sup>

### Foreign body infection model

The foreign body infection model was divided into 5 methods according to the different types of the foreign bodies induced infections, including 1) suture, 2) catheter, 3) filter paper, 4) microcarrier beads, and 5) sand. The wound is made from superficial site down to muscle.



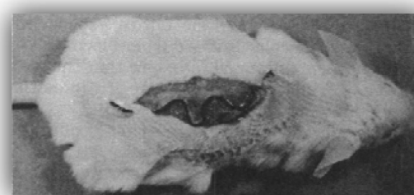
**Figure 6** Preheated double brass block burn procedure. I = the back of mouse was shaved, II = elevate skin folder on the back, III = preheated double brass block were press down on the skin folder, IV = bacterial suspension is applied to the burn surface<sup>19</sup>

### Suture infection model

This model was developed by McRipley and Whitney<sup>23</sup> by creating superficial surgical incision on the back of a mouse. A female CF-1 mouse was anesthetized and the back was shaved. The thread was cut into a 5

cm-segmented and put into boiling water for 5 min. The segmented thread was allowed to cool down and removed excess water by absorbing with a sterile paper. The segmented thread was placed into bacterial suspension (*S. aureus* or *P. aeruginosa*) and mixed on a vortex mixer for 10 s. The segmented was allowed to soak in the inoculum for 30 min. Approx.  $10^3$  cells were adsorbed on each segment of thread during this period. The segment was removed from the bacterial suspension and dried before using. The superficial longitudinal midline incision,  $2.3\pm0.2$  cm in length, was produced extending down to the panniculus carnosus. The other side of the incision was retracted. The contaminated suture inserted through the to produce infection by a suturing needle. The end of the suture was fixed with rubber cement. The wound was eventually covered approx. 6% total body surface area of the mouse (Figure 7). Tissue bacterial count was done by homogenizing the biopsy sample from the infected wound.

In 2007 Yarbboro et al.<sup>24</sup> used a gauge stainless-steel suture to promote infection. An adult female Sprague-Dawley rat was anesthetized. The lateral aspect of the right thigh was shaved and cleaned with povidone iodine before being incised with scissors to open a 10 mm-longitudinal. The blunt dissection was done to form the pocket  $2\times2$  cm<sup>2</sup> in the quadriceps muscle down to the femur. To promote the infection, a 32-gauge stainless-steel suture was placed inside the wound around the femur. Gentamicin-sensitive *S. aureus* suspension ( $8.0\times10^5$  CFU) is pipetted into the pocket. The incision is superficially closed with skin clips. The specimen from the wound is obtained for quantitative culture. High mortality is observed (6 of 9).



**Figure 7** Superficial incision suture model<sup>23</sup>

### Catheter infection model

The foreign body infection using a catheter was performed by Espersen et al.<sup>25</sup> An adult female CF-1 mouse is anesthetized. The silicone catheter with a 2.8 mm-internal diameter and a 4.9 mm-external diameter was cut into 1.5 cm. The segmented catheter was contained 2 ml of beef broth supplemented with 20% (v/v) citrated human blood and incubated at 37°C for 3 d. On the day of infection, the mouse was incised for 1 cm on the lateral abdomen under sterile technique. The catheter was left in the peritoneal cavity and closed. After the operation for 18 h, the suture was removed. At approximately 1 h after the operation, the infection is produced by intraperitoneal injection of 1 ml-*S. aureus* E2371 at various concentrations ( $2.1 \times 10^3$  to  $2.5 \times 10^9$  CFU) into the lateral abdominal wall opposite the catheter operated wound. A challenge dose greater than  $1 \times 10^5$  CFU gives nearly 100% infection rate, while an inoculum of greater than  $5 \times 10^8$  CFU results in mortality. The infection persists at least 30 d, an intra-abdominal abscess surrounding the catheter is observed. Microscopy was done; smears were made from the catheter washing and aspirates. The light microscopy is established for quantitative assessment.

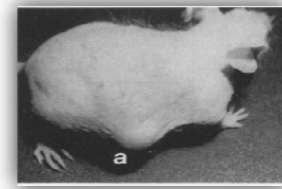
### Filter paper infection model

In 1982, Actor and Grappel<sup>26</sup> performed the infection in a mouse using a filter paper disc as a foreign body. The albino Webster-derived CD-1 mouse was anesthetized. The incision was created in the midline of ventral abdomen. The infection was made by soaking filter paper disc (6.35 mm-diameter) with 10% sterile carrageenan solution mixed with microorganisms (*Bacteroides fragilis* and *Escherichia coli* of  $10^5$ - $10^8$  CFU) and placed in the underlying subcutaneous tissue. The organisms spread from the local site and lethality was reported.

### Microcarrier beads infection model

Another foreign body model was reported by Ford et al.,<sup>27</sup> Bunce et al.,<sup>28</sup> and Engleberg et al.<sup>29</sup> using organism mix with microcarrier beads (Cytodex-I®). Microcarriers act as the abscess promoter in the formation of subcutaneous abscess. Dextran or gelatin microbeads

are mixed with *S. aureus* ( $2 \times 10^6$  CFU) and subcutaneously injected into the CF-1.<sup>27</sup> The abscess that developed with microcarriers was attained a diameter of up to 1.5 cm and persisted for several days (Figure 8).

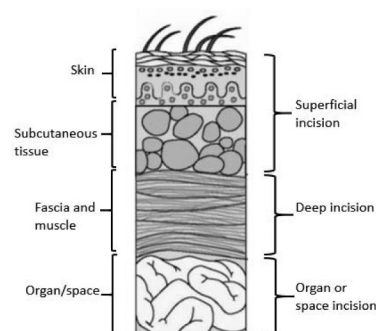


**Figure 8** Microbeads mixed with inoculum induced abscess at the day 12 after the infection<sup>28</sup>

### Sand induced infection model<sup>30</sup>

A male SD rat was anesthetized and kept warm during the surgery on a heating pad. Hair on the back was clipped. The skin is incised through the back skin, parallel to the vertebral column (5 mm-lateral and 4 cm in length). The 1 cm-depth-incision underlies into paraspinous muscle. To promote the infection, sterile sand (100 mg) was placed in the wound and inoculated with 100 µl of MRSA suspension ( $5.0 \times 10^7$  CFU). The wound was closed with surgical staples. Three days after the infection, lethality was observed. On the third day of the post-infection, the survival animal was re-anesthetized. The paraspinous incision was examined for clinical evidence of the infection. Presence of an abscess or frank pus within the wound is defined.

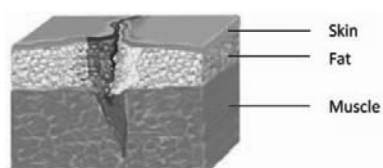
The depth of the surgical infection-site (Figure 9) with the foreign body was classified into superficial, deep, and organ or space incisions. The superficial incisions were reported by McRipley and Whitney,<sup>23</sup> Espersen et al.,<sup>25</sup> Actor and Grappel,<sup>26</sup> and Ford et al.<sup>27</sup> The deep incision was described by Fallon et al.<sup>30</sup> and the organ or space incision was reported by Yarboro et al.<sup>24</sup> For deep and organ incision, it requires a larger animal than a small rodent because the size of a small rodent is not sufficient to perform the lesion.



**Figure 9** The depth of incision is classified as superficial, deep, and organ or space incision<sup>19</sup>

### Lacerated wound infection model

A lacerated wound was results from a blunt trauma involved separation of skin or other tissue, i.e., tendon, ligament, muscle, blood vessel, or bone (Figure 10). This model has been developed in a rat and a guinea pig. The wound is performed by making incisions in various length and depth. This model is divided into 2 methods depending on appearance of the lesion including non-crushed and crushed lacerated wounds.



**Figure 10** Schematic depiction of laceration wound<sup>19</sup>

### Non-crushed lacerated wound infection

The first lacerated wound infection in an animal was examined by Edlich et al.<sup>31</sup> An albino guinea pig was employed. The hair on the back was depilated and cleaned. Two to three cm-incisions was made parallel and equidistant from the vertebral column through the subcutaneous tissue down to the fascia using a modified non-crushing intestinal clamp and a surgical blade. After the incision for 5 min, 10 µl of bacterial suspension containing  $10^7$  CFU of *S. aureus* was introduced to the wound. At the end of the experiment, purulent exudate was observed.

### Crushed lacerated wound infection

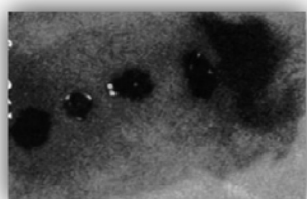
A guinea pig was used to design an animal bite wound model by inoculation three species of organisms on the crushed incision.<sup>32</sup> An adult albino guinea pig was anesthetized. The dorsal hair was clipped and removed with a hair remover agent. The skin was cleaned with 70% ethanol and povidone-iodine solution. The dorsum was cut by four paravertebral lacerations (2 cm-long and 2 cm-apart) using a no. 15-scalpel. The hemostat was clamped along the wound edge for 1.5 cm-length of the epidermal/dermal junction to make the crush for 5 s. The inoculum was prepared by mixing various bacteria strains including *S. aureus*, *B. fragilis* and *Pasteurella multocida* ( $4\text{--}6 \times 10^8$  CFU/ml) before an 0.4 ml-aliquot of inoculum was loaded into the wound. Each wound was covered with a transparent dressing. Erythema, induration, and purulence were observed at was day 6 of the bacterial inoculation. The tissue specimen was weighed immediately after the excision followed by performing microbiology laboratory for quantitative bacteriologic analysis.

### Excisional wound infection model

Excisional wound infection was performed by removing the target tissue by excisional surgery. The shape of the wound was either square or round. Most of excisional wounds are produced by removal of only the full-thickness skin, but not injured underlying muscle.

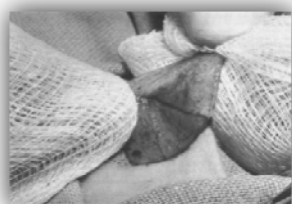An adult male BALB/c mouse was anesthetized.<sup>33</sup> The back was shaved and depilated. The four full thickness excisional wounds were made along the dorsal surface using surgical scissors and forceps. The size of wound is approx.  $8 \times 12.5 \text{ mm}^2$  and each wound had at least a 5 mm-unbroken skin. The base of the wound was panniculus carnosus. The microorganism ( $5 \times 10^6$  cells of mid-log phase bioluminescent *E. coli*) in a 50 µl-PBS was applied to the wound. The infected wound in the living mouse showed only a slight loss of bacterial luminescence over a period of 4 h (Figure 11).

A punch biopsy instrument makes an excisional wound. An adult female mutant diabetic mouse was used. The hair on the dorsum is clipped gently. The excisional wound was prepared on the shaved back using a punch biopsy instrument (3 mm-diameter). Each wound was inoculated by a 30 µl bacterial suspension ( $1 \times 10^5$  CFU of MRSA in PBS) and covered with a sterilized transparent dressing. The wound was stained with hematoxylin and eosin (H&E) to follow up the infection. Gram staining of the MRSA-infected wound shows numerous gram-positive cocci.<sup>34</sup>



**Figure 11** Bioluminescence images of four excisional wounds at the 24 hours post-infection<sup>33</sup>

In another study, an adult Lewis or Sprague Dawley rat was anesthetized and sheared dorsally. The incision was made to the skin, dorsolaterally just anterior to the pelvis approx. 1 inch<sup>2</sup> under sterile technique. The depth of the incision extended through the full thickness of skin, but it does not injure the panniculus carnosus or underlying muscle. The anteromedial corner of the incised skin was lifted with a toothed forceps and carefully dissected away from the panniculus using the index finger wrapped in a gauze pad (Figure 12). *P. aeruginosa* ( $10^7$  CFU) was pipetted to the wound above the panniculus carnosus.<sup>35</sup> Quantitative extraction of bacteria from the surface wounds was done.



**Figure 12** Removal technique of the full thickness skin flap<sup>35</sup>

## Conclusions

Animal models have become a standard tool for the study of a wide array of external wound infection. The models are different in species of animals, strains and concentration of microorganisms, the wound types, including the depth and location of the wound. The animals usually employed include mouse, rat, rabbit, and guinea pig. The strains of microorganisms commonly investigated are aerobic bacteria, i.e., *S. aureus*, *S. epidermidis*, *S. saprophyticus*, and *P. aeruginosa*.

The skin abrasion model was classified into 5 methods. Either dorsal or abdominal surface was abraded by different instruments including elastic bandage, needle, blade, sand surface material, and dermatome, which are commonly available. The procedure was not complicated, except the dermatome model. The animal was injured at the superficial level and can survive for a long period of the investigation.

The burn wound infection was divided by sources of heating or burning, including gas flame, burning ethanol bath, boiling water, pre-heated single metal bar, and pre-heated double brass block. The skin was burned in the range of 5 – 30% total body surface area. The infection was induced by applying the organism on the burned surface. The survival rate was recorded and the lesion was homogenized for microbiological investigation. The mortality rate was observed. However, this model was not suitable for a long term-study.

The foreign body infection models were reported with several materials including segmented suture, segmented catheter, filter paper disc, microcarrier beads, and sand. The depth of the wound was classified into three layers, e.g., superficial (down to the muscle), deep (1-2 cm into the muscle), and organ or space incision. The surgical site was made in different locations such as abdomen, back, thigh, and flank. The assessment was commonly done by quantitative determination of bacteria in the homogenized tissue.



**Table 1.** Induction of external wound infection in experimental animals.

| <b>Models</b>  | <b>Procedure</b>   | <b>Remark</b>   |
|--|--|---|
| <b><i>Skin abrasion infection model</i></b>                |  |   |
| Mouse-BALB/C, CF-1, SKH1                                   | The animal is anesthetized and shaved on the target skin. The instrument (elastic bandage, needle, blade, sand surface equipment, and electro-dermatome) is used to make skin-abrasion. The inoculum is applied on the wound to promote the infection.   | The animal is injured only the superficial level and can survive for a long period.   |
| <b><i>Burn wound infection</i></b>                         |  |   |
| Mouse-SCIDbg, CD-1, ND4 Swiss Webster Guinea pig           | The animal is anesthetized and shaved on the target skin. Gas flame, boiling water, ethanol, preheated metal bar, or brass block is used as a heating source to make eschar on the skin. The normal saline may use for resuscitation. The bacterial suspension is applied on the burn skin or injected subcutaneously. | The size of burn range from 5%-30% total body surface area. The mortality rate is observed.   |
| <b><i>Foreign body infection model</i></b>                 |  |   |
| Mouse-CF-1, Albino Webster-derived CD-1 Rat-Sprague-Dawley | The animal is anesthetized and shaved on the target skin. Thread suture, stainless steel suture, segmented catheter, filter paper disc, microcarrier beads, or sterile sand is placed in the incision to introduce the infection. The organism is applied to the wound or injected subcutaneously.                     | The depth of this model is classified into superficial, deep and organ/space infection.   |
| <b><i>Lacerated wound infection model</i></b>              |  |   |
| Guinea pig   | The animal is anesthetized and shaved on the target skin. The incision is made down to the fascia and the bacterial suspension is applied to the wound. The hemostat is used for clamp along the wound edge before the infection in the crushed-lacerated wound.   | Deep laceration with devitalized tissue is more prone to infection.   |
| <b><i>Excisional infection model</i></b>                   |  |   |
| Mouse-BALB/C Rat-Sprague-Dawley                            | The animal is anesthetized and shaved on the target skin. Full thickness wound is prepared on the skin in various sites using scissors, punch biopsy instrument, or scalpel. The wound is inoculated with bacterial suspension.  | The excisional wound is produced by removing the full thickness skin but no injury to the underlying muscle and resulting in prolong healing. |

## References

1. Cheadle WG, Turina M. Infection and organ failure in the surgical patient: a tribute to seminal contributions by Hiram C. Polk, Jr, MD. *Am J Surg* 2005;190:173-7.
2. Zak O, O' Reilly T. Animal models in the evaluation of antimicrobial agents. *Antimicrob Agents Chemother* 1991;35:1527-31.
3. Kugelberg E, Norström T, Petersen TK, Duvold T, Andersson DI, Hughes D. Establishment of a superficial skin infection model in mice by using *Staphylococcus aureus* and *Streptococcus pyogenes*. *Antimicrob Agents Chemother* 2005;49:3435-41.
4. Pastagia M, Euler C, Chahales P, Fuentes-Duculan J, Krueger JG, Fischetti VA. A Novel chimeric lysin shows superiority to mupirocin for skin decolonization of methicillin-resistant and sensitive *Staphylococcus aureus* strains. *Antimicrob Agents Chemother* 2001;55:738-44.
5. Dai T, Tegos GP, Zhiyentayev T, Mylonakis E, Hamblin MR. Photodynamic therapy for methicillin-resistant *Staphylococcus aureus* infection in a mouse skin abrasion model. *Laser Surg Med* 2010;42:38-44.
6. Kraft WG, Johnson PT, David BC, Morgan DR. Cutaneous infection in normal and immunocompromised mice. *Infect Immun* 1986;52:707-13.
7. Leyden JJ, Stewart R, Kligman AM. Experimental infections with group A streptococci in humans. *J Invest Dermatol* 1980;75:196-201.
8. Roche ED, Renick PJ, Tetens SP, Carson DL. A model for evaluating topical antimicrobial efficacy against methicillin-resistant *Staphylococcus aureus* biofilms in superficial murine wounds. *Antimicrob Agents Chemother* 2012;56:4508-10.
9. Katakura T, Yoshida T, Kobayashi M, Herndon DN, Suzuki F. Immunological control of methicillin-resistant *Staphylococcus aureus* (MRSA) infection in an immunodeficient murine model of thermal injuries. *Clin Exp Immunol* 2005;142:419-25.
10. Shigematsu K, Asai A, Kobayashi M, Herndon DN, Suzuki F. *Enterococcus faecalis* translocation in mice with severe burn injury: a pathogenic role of CCL2 and alternatively activated macrophages (M2aMΦ and M2cMΦ). *J Leukoc Biol* 2009;86:999-1005.
11. Steritz DD, Holder IA. Experimental studies of the pathogenesis of infections due to *Pseudomonas aeruginosa*: description of a burned mouse model. *J Infect Dis* 1975;131:688-91.
12. Cryz SJ, Fürer E, Germanier R. Prevention of fatal experimental burn-wound sepsis due to *Klebsiella pneumoniae* KP1-O by immunization with homologous capsular polysaccharide. *J Infect Dis* 1984;150:817-22.
13. Cryz SJ, Fürer E, Germanier R. Experimental *Klebsiella pneumoniae* burn wound sepsis: role of capsular polysaccharide. *Infect Immun* 1984;43:440-1.
14. Felts AG, Giridhar G, Grainger DW, Slunt JB. Efficacy of locally delivered polyclonal immunoglobulin against *Pseudomonas aeruginosa* infection in a murine burn wound model. *Burns* 1999;25:415-23.
15. Rumbaugh KP, Griswold JA, Iglewski BH, Hamood AN. Contribution of quorum sensing to the virulence of *Pseudomonas aeruginosa* in burn wound infections. *Infect Immun* 1999;67:5854-62.
16. McVay CS, Velásquez M, Fralick JA. Phage therapy of *Pseudomonas aeruginosa* infection in a mouse burn wound model. *Antimicrob Agents Chemother* 2007;51:1934-8.
17. Orenstein A, Klein D, Kopolovic J, Winkler E, Malik Z, Keller N, et al. The use of porphyrins for eradication of *Staphylococcus aureus* in burn wound infections. *FEMS Immunol Med Microbiol* 1997;19:307-14.
18. Stevens EJ, Ryan CM, Friedberg JS, Barnhill RL, Yarmush ML, Tompkins RG. A quantitative model of invasive *Pseudomonas* infection in burn injury. *J Burn Care Res* 1994;15:232-5.
19. Dai T, Kharkwal GB, Tanaka M, Huang YY, Bil de Arce VJB, Hamblin MR. Animal models of external traumatic wound infections. *Virulence* 2011;2:296-315.
20. Dai T, Tegos GP, Lu Z, Huang L, Zhiyentayev T, Franklin MJ, et al. Photodynamic therapy for *Acinetobacter baumannii* burn infections in mice. *Antimicrob Agents Chemother* 2000;53:3929-34.

21. Dai T, Tegos GP, Burkatovskaya M, Castano AP, Hamblin MR. Chitosan acetate bandage as a topical antimicrobial dressing for infected burns. *Antimicrob Agents Chemother* 2009;53:393-400.
22. Ragàs X, Sánchez-García D, Ruiz-González R, Dai T, Agut M, Hamblin MR, Nonell S. Cationic porphycenes as potential photosensitizers for antimicrobial photodynamic therapy. *J Med Chem* 2010;53:7796-803.
23. McRipley RJ, Whitney RR. Characterization and quantitation of experimental surgical-wound infections used to evaluate topical antibacterial agents. *Antimicrob Agents Chemother* 1976;10:38-44.
24. Yarbboro SR, Baum EJ, Dahners LE. Locally administered antibiotics for prophylaxis against surgical wound infection. *J Bone Joint Surg* 2007;89:929-33.
25. Espersen F, Frimodt-Møller N, Corneliussen L, Riber U, Rosdahl VT, Skinhøj P. Effect of treatment with methicillin and gentamicin in a new experimental mouse model of foreign body infection. *Antimicrob Agents Chemother* 1994;38:2047-53.
26. Actor P, Grappel SF. Efficacy of ceftizoxime and related compounds in animal models of infection. *J Antimicrob Chemother* 1982;10:81-9.
27. Ford CW, Hamel JC, Stapert D, Yancey, RJ. Establishment of an experimental model of a *Staphylococcus aureus* abscess in mice by use of dextran and gelatin microcarriers. *J Med Microbiol* 1989;28:259-66.
28. Bunce C, Wheeler L, Reed G, Musser J, Barg N. Murine model of cutaneous infection with gram-positive cocci. *Infect Immun* 1992;60:2636-40.
29. Engleberg NC, Heath A, Miller A, Rivera C, DiRita VJ. Spontaneous mutations in the CsrRS two-component regulatory system of *Streptococcus pyogenes* result in enhanced virulence in a murine model of skin and soft tissue infection. *J Infect Dis* 2001;183:1043-54.
30. Fallon MT, Shafer W, Jacob E. Use of cefazolin microspheres to treat localized methicillin-resistant *Staphylococcus aureus* infections in rats. *J Surg Res* 1999;86:97-102.
31. Edlich RF, Tsung MS, Rogers W, Rogers P, Wangenstein OH. Studies in management of the contaminated wound: I. Technique of closure of such wounds together with a note on a reproducible experimental model. *J Surg Res* 1968;8:585-92.
32. Lammers R, Henry C, Howell J. Bacterial counts in experimental, contaminated crush wounds irrigated with various concentrations of cefazolin and penicillin. *Am J Emerg Med* 2001;19:1-5.
33. Hamblin MR, O'Donnell DA, Murthy N, Contag CH, Hasan T. Rapid control of wound infections by targeted photodynamic therapy monitored by *in vivo* bioluminescence imaging. *Photochem Photobiol* 2002;75:51-7.
34. Shi CM, Nakao H, Yamazaki M, Tsuboi R, Ogawa H. Mixture of sugar and povidone-iodine stimulates healing of MRSA-infected skin ulcers on db/db mice. *Arch Dermatol Res* 2007;299:449-56.
35. Saymen DG, Nathan P, Holder IA, Hill EO, Macmillan BG. Infected surface wound: an experimental model and a method for the quantitation of bacteria in infected tissues. *Appl Microbiol* 1972;23:509-14.